

Improvement in vision with inverted placement of an asymmetric refractive multifocal intraocular lens

Chandra Bala, PhD, MB BS(Hons), FRANZCO, Kerrie Meades, MB BS(Hons), FRANZCO

We report the case of a 73-year-old man who presented for bilateral cataract surgery. He was noted to have a 0.5 mm corneal scar inferonasally at the pupil margin in his right eye. Uneventful bilateral cataract surgery was performed. An asymmetric toric refractive multifocal intraocular lens (IOL) (LU-313MF30T, Lentis MPlus toric) was implanted in the right eye. Postoperatively, the uncorrected distance visual acuity (UDVA) in that eye was 6/6⁻³, the uncorrected intermediate visual acuity at 60 cm was J4, and the uncorrected near visual acuity (UNVA) at 40 cm was J8. The patient was not satisfied with the UNVA. Corneal topography showed 3.0 diopters (D) of corneal flattening over the +3.00 D near segment. The IOL was rotated 180 degrees, which improved the UNVA to J1 while maintaining the UDVA. This study demonstrates that the Lentis Mplus can function even when the near segment is not positioned inferiorly.

Financial Disclosure: Neither author has a financial or proprietary interest in any material or method mentioned.

J Cataract Refract Surg 2014; 40:833–835 © 2014 ASCRS and ESCRS

Multifocal intraocular lenses (IOLs) have gradually become an accepted option in cataract surgery. The Lentis Mplus (Oculentis GmbH) is an asymmetric refractive multifocal IOL that has been used extensively and has evolved to a plate haptic. This asymmetric refractive IOL is unusual in not refracting light symmetrically around the optical axis. It is designed with a 6.0 mm optic and a +3.0 diopter (D) near segment, which is implanted so the near segment is inferior to the visual axis. We present a case that shows the effectiveness of this IOL in the inverted position; ie, with the near segment on top.

CASE REPORT

A 73-year-old man presented for cataract surgery requesting a Lentis Mplus multifocal IOL similar to the IOL his wife had. At presentation, the uncorrected distance visual acuity (UDVA) was 6/9 in each eye and he had no recollection of ocular trauma. A 0.5 mm corneal scar inferonasal to the pupil center at the pupil margin was noted in the right eye. The keratometry values were 42.51@87/44.58@177 in the right eye and 43.72@88/44.35@178 in the left eye. Since the scar was not large, the preoperative subjective refraction differed from the keratometry, and the scar was oblique to the keratometric cylinder axis, the astigmatism was not attributed directly to the scar.

Uneventful sequential cataract surgery was performed in the left eye and 1 month later, in the right eye. An 18.5 D asymmetric nontoric refractive multifocal IOL (LU-313MF30), Lentis Mplus [Oculentis GmbH] was implanted in the left eye. A customized toric IOL of +17.6 +2.79 × 177 (LU-313MF30T, Lentis MPlus toric) was implanted in the right eye. The customized IOL was inserted through a clear corneal temporal incision and rotated to align the toric axis. This alignment automatically resulted in the near segment being placed inferiorly (Figure 1, A).

Postoperatively, the UDVA in the left eye was 6/5; the uncorrected intermediate visual acuity (UIVA) at 60 cm was J8, and the uncorrected near visual acuity (UNVA) at 40 cm was J4. The right eye was targeted at -0.25 D. Postoperatively, the UDVA was 6/6⁻³, the UIVA was J4, and the UNVA was J8. The patient was unhappy with the UNVA in the right eye. The subjective refraction in that eye was plano -0.25 × 90.

Submitted: December 14, 2013.

Final revision submitted: January 6, 2014.

Accepted: January 7, 2014.

From the Department of Ophthalmology (Bala), Australian School of Advanced Medicine, Macquarie University, and Personal Eyes (Meades), Sydney, Australia.

Corresponding author: Chandra Bala, PhD, MB BS(Hons), FRANZCO, Department of Ophthalmology, Australian School of Advanced Medicine, Macquarie University, Sydney, NSW, Australia. E-mail: chandrabala.eye@gmail.com.




Figure 1. A: Retroillumination slitlamp image demonstrating the corneal scar and the underlying toric IOL with the near segment positioned inferiorly. The white interrupted circle marks the scar. B: Retroillumination slitlamp image demonstrating the corneal scar and the underlying toric IOL with the near segment positioned superiorly (confirmed by the single tab at the inferotemporal edge of the optic, marked by a rectangle). The near segment is outlined by the interrupted white line.

Scanning-slit corneal topography (Orbscan, Bausch & Lomb) of the right eye showed 3.0 D of flattening inferior to the pupil on the axial power map at 4.0 mm diameter (Figure 2). The 3.0 mm zone had an irregularity of ± 1.1 D and the 5.0 mm zone, of ± 1.4 D. There was no significant difference in higher-order aberrations between the 2 eyes on Hartmann-Shack aberrometry (Zywave, Bausch & Lomb).

After 3 months of observation, with the use of lubrication in the right eye and following extensive discussions regarding treatment options for this eye, the IOL was rotated 180 degrees, which resulted in the near segment being placed superior to the visual axis (Figure 1, B). The toric axis of the IOL remained unchanged. The UDVA improved to 6/5, and the UNVA improved to J1; the UIVA remained unchanged at J8. The patient now prefers the right eye as it is his dominant eye and the flare of light from the near segment is directed upward and is less bothersome than in the left eye.

DISCUSSION

The Lentis Mplus is an asymmetric refractive multifocal IOL and, similar to other multifocal IOLs,

projects images of far and near objects on the retina simultaneously. Unlike symmetric IOLs, the near segment is shaped like a partial doughnut and is conventionally placed inferiorly, similar to bifocal spectacles. It has been used extensively in this manufacturer-recommended orientation.¹⁻⁵ However, IOLs move with eye movement and therefore their mechanism cannot resemble those of bifocal spectacles. In the recommended inferior orientation of the near segment, near vision is achieved by refracting only the inferior rays. This leaves a bigger effective area for distance vision. The center and the portion of IOL outside the near segment generate the image of distant objects.

In our case, the impact of the 0.5 mm small corneal scar on astigmatism and the localized corneal flattening were not fully appreciated preoperatively. In hindsight, the asymmetric astigmatism should have warranted preoperative corneal topography.

Following the initial insertion of the IOL with the near segment located inferiorly, the light rays incident on the superior cornea and the majority of the pupil were appropriately refracted by the monofocal/nonreading portion of the toric IOL. The topography measurement of corneal irregularity within the 3.0 mm zone and the 5.0 mm zone were only ± 1.1 D and ± 1.4 D, respectively. Therefore, the scar did not contribute significantly to irregular astigmatism within the 2 zones. This explains how the patient was able to achieve good spectacle-corrected vision preoperatively and good uncorrected distance vision postoperatively.

The near segment refracted some of the rays entering the inferior pupil, allowing intermediate vision, but the majority of the 3.0 D near segment was neutralized by the 3.0 to 4.0 D flattening of the overlying cornea. This outcome raises the possibility of correcting asymmetric astigmatism with asymmetric IOLs. Perhaps in the future we will be able to

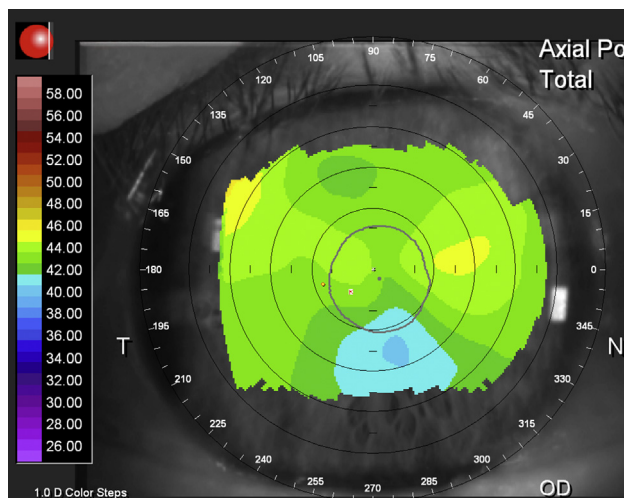


Figure 2. Axial power topography map (scanning-slit corneal topography) demonstrating 3.0 D of corneal flattening inferior to the pupil.

design topography/wavefront-guided IOLs to correct greater amounts of irregular astigmatism (as in keratoconus).

Following inversion of the IOL by 180 degrees, the toric axis remained aligned but the near segment was moved to an area covered by normal cornea (Figure 1, B). Rotating the IOL so the near segment was placed superiorly allowed it to function unencumbered, resulting in better near vision. Since the light inside the 3.0 mm pupil, rather than the light passing through the inferior cornea, dominates the distance vision, the distance vision remained unaffected. In summary, by rotating the IOL, the distance segment was in front of the flattened area but due to the bigger effective area of the distance segment and the central notch of the near segment, the visual outcome for distance was unaffected.

The present study highlights the importance of corneal topography (Figure 2) even if the corneal scars are small. It also demonstrates the ability of the Lentis Mplus IOL to work in positions other than the vertical orientation (recommended by the manufacturer) with the near segment placed inferiorly and its ability to withstand less than ideal corneal topography. Finally, this study raises the possibility of correcting irregular astigmatism with topography/wavefront-guided custom-designed IOLs in the future, allowing correction of diseases with irregular astigmatism such as keratoconus.

REFERENCES

1. Alió JL, Piñero DP, Plaza-Puche AB, Rodríguez Chan MJ. Visual outcomes and optical performance of a monofocal intraocular lens and a new-generation multifocal intraocular lens. *J Cataract Refract Surg* 2011; 37:241–250
2. Alió JL, Plaza-Puche AB, Javaloy J, Ayala MJ. Comparison of the visual and intraocular optical performance of a refractive multifocal IOL with rotational asymmetry and an apodized diffractive multifocal IOL. *J Refract Surg* 2012; 28:100–105
3. Khoramnia R, Auffarth GU, Rabsilber TM, Holzer MP. Implantation of a multifocal toric intraocular lens with a surface-embedded near segment after repeated LASIK treatments. *J Cataract Refract Surg* 2012; 38:2049–2052
4. Venter J, Pelouskova M. Outcomes and complications of a multifocal toric intraocular lens with a surface-embedded near section. *J Cataract Refract Surg* 2013; 39:859–866
5. Alió JL, Plaza-Puche AB, Javaloy J, Ayala MJ, Vega-Estrada A. Clinical and optical intraocular performance of rotationally asymmetric multifocal IOL plate-haptic design versus C-loop haptic design. *J Refract Surg* 2013; 29:252–259



First author:

Chandra Bala, PhD, MB BS(Hons),
FRANZCO

*Australian School of Advanced Medicine,
Macquarie University, Sydney,
NSW, Australia*