



Important parameters included documentation of the severity of retinopathy (if present), the presence of macular pathology and the eye(s) affected.

Results showed that when retinopathy is present, 16.2% of O-O&O did not clearly differentiate vision-threatening retinopathy from milder forms of retinopathy and 38.3% of correspondence did not comment on the presence of macular pathology. If retinopathy was reported, only 53.3% of letters from O-O&O specified the affected eye(s).

Information in the report from O-O&O as well as its dissemination to appropriate clinicians can have significant implications for a patient's diabetes care. Treating doctors often rely on it when individualizing a patient's glycaemic target. With the current strain on healthcare resources, public eye clinic appointments can be utilized more efficiently so that patients in whom vision-threatening retinopathy is identified can access prompt intervention. Some patients with significant retinopathy fail to have regular follow-up eye consultations because of the time and costs involved. If the treating doctor knows that a patient has vision-threatening retinopathy likely to require intervention (rather than just monitoring) and conveys this message clearly, the patient may be more prepared to attend follow-up.

Our findings could serve as a stimulus for generating a dialogue between healthcare providers on what is the optimal format to convey pertinent eye care information in correspondence. A standardized reporting format and pathway would likely improve the chance of information being appropriately directed and acted upon. This is consistent with the stated aim of the National Diabetes Strategy. We would advocate using a numerical grading approach similar to the National Health Service Diabetes Eye Screening Programme of R0, R1, R2, M1 and M2 and so on.<sup>1</sup> The now widely adopted numerical Bethesda System for reporting thyroid cytology has greatly facilitated the interpretation of biopsy results.<sup>2</sup> The adoption of a numerical format should not undermine the importance of a more descriptive report with recommendations, but it will minimize ambiguity in what the eye care professionals think should be undertaken. Similarly, this framework is not intended to replace ongoing professional training or override local guidelines for referral but should ideally facilitate both processes. Another advantage of a numerical reporting system is the ability to foster the collection of uniform diabetes eye data for research.

We propose that a working party of ophthalmologists, optometrists, endocrinologists, diabetes educators, general practitioners and other interested parties be assembled to discuss the feasibility of moving in this direction.

Eddy J Tabet MBBS(Hons),<sup>1,2</sup>

Maria I Constantino BInfoTech,<sup>1,2</sup>

Jencia Wong PhD<sup>1,2</sup> and Dennis Yue PhD<sup>1,2</sup>

<sup>1</sup>*Discipline of Medicine, The University of Sydney, and*

<sup>2</sup>*Diabetes Centre, Royal Prince Alfred Hospital, Sydney, New South Wales, Australia*

Received 13 November 2016; accepted 17 November 2016.

## REFERENCES

1. Taylor D. Diabetic eye screening revised grading definitions, NHS v1.3, November 2012.
2. Cibas ES, Syed AZ. The Bethesda System for Reporting Thyroid Cytopathology. *Am J Clin Pathol* 2009; **132**: 658–65.

## Novel topical therapy for corneal blood staining

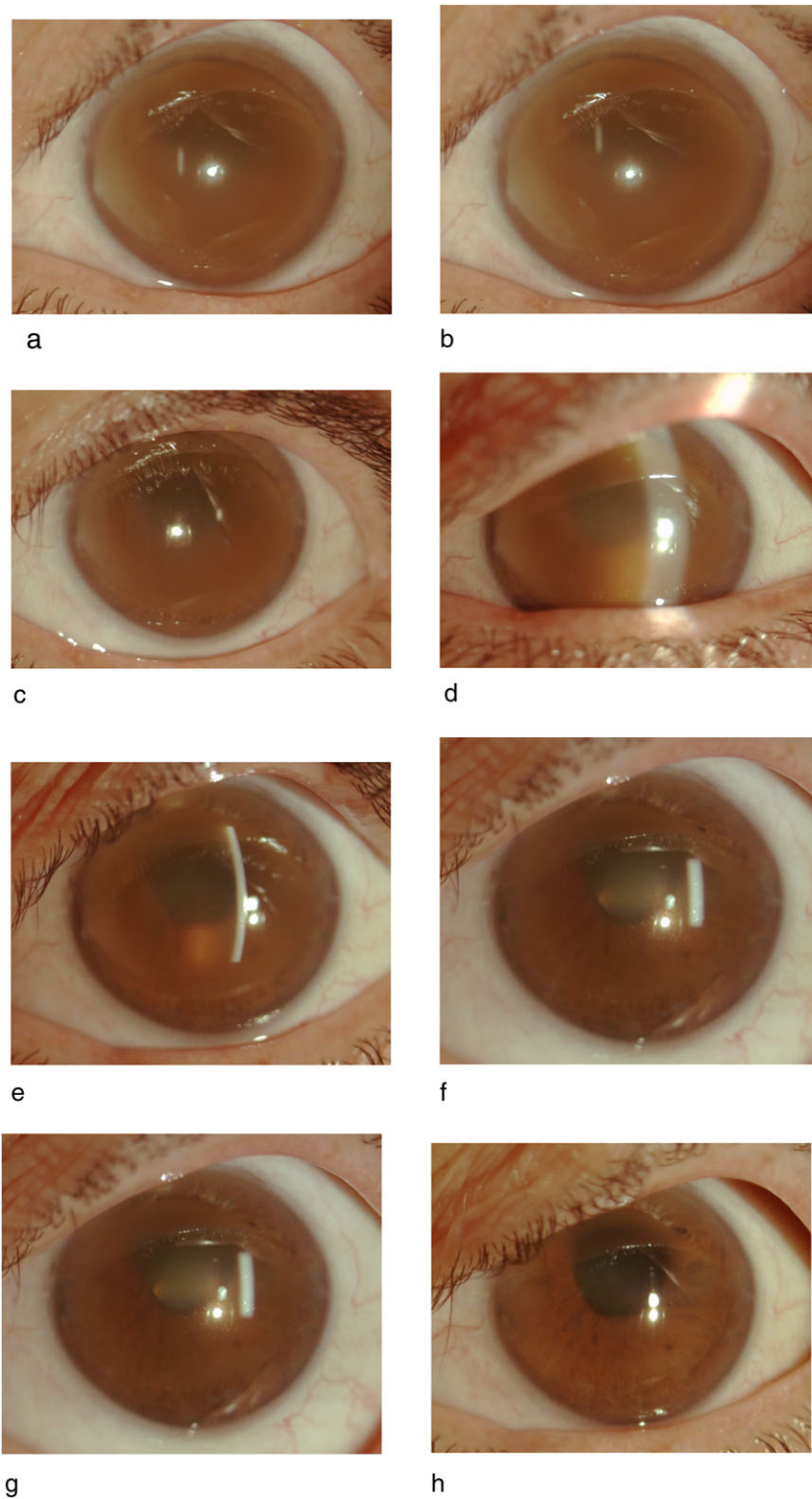
A 67-year-old gentleman underwent trabeculectomy for end-stage primary open-angle glaucoma (cup-to-disc ratio 0.95). He was on dual antiplatelet agents (ticagrelor and aspirin) for cardiac stents, which could not be ceased. Four days after uncomplicated surgery, he took oxycodone, which caused severe nausea and vomiting. He developed a complete hyphema with an intraocular pressure (IOP) of 60 mmHg. Two anterior chamber washouts were needed to evacuate the blood from the anterior chamber, after which corneal blood staining was noted. The vision declined from 6/6 pre-operatively to hand motion.

One year after his trabeculectomy, his dense corneal blood staining remained unchanged (visual acuity hand motion; IOP 9 mmHg). Following extensive discussions about various treatment options, the patient was commenced on deferiprone (20 mcg/mL in 10 mL of normal Saline) three times a day for 1 month. No significant improvement or side effects were seen and therefore the administration was increased to four times a day. After 2–3 months, the cornea started clearing and iris features could be identified (Fig. 1). By 10 months, the cornea was clear enough to view the optic disc, which was almost cupped out. His vision improved to 6/75 (ph 6/36). The endothelial cell count at last visit was 1455 cells/sqmm (contralateral eye 2577 cells/sqmm).

Histologically, corneal blood staining demonstrates intracellular and extracellular depositions of

*Competing/conflicts of interest:* None declared.

*Funding sources:* None declared.



**Figure 1.** Slit lamp photo of the cornea showing a gradual clearing of the corneal blood staining with topical deferiprone. (a) Baseline (1 year after trabeculectomy). (b) 1 month post three times a day deferiprone. (c–h) 2, 3, 4, 6, 8 and 10 months on qid deferiprone from initial commencement of treatment.

haemosiderin.<sup>1</sup> This is similar to that seen in other iron overload states such as following repeated blood transfusion for thalassemia. In managing this patient, there were three treatment options: observation, iron

chelation or penetrating keratoplasty. Corneal blood staining has been managed conservatively in the past. In those reports, the staining took 2 to 3 years to clear spontaneously.<sup>2,3</sup> In the present case, after

1 year of observation, the corneal staining remained dense. Based on the photos of patients published in the literature, it was felt that our patient could take another 4 or more years to clear.

Desferrioxamine, a parenteral iron-chelating agent, has been used topically to treat corneal blood staining. It has a high molecular weight of 656.79 g/mol and is hydrophilic in nature. The corneal epithelium is relatively impervious to hydrophilic substances that are greater than 60–100 g/mol. Hence, it is not surprising that desferrioxamine has been ineffective in treating corneal blood staining.<sup>4</sup>

A penetrating keratoplasty could have been performed. However, the active use of anticoagulants and the history of bleeding were important deterrents. Furthermore, there was concern of reduced visual potential due to the high IOPs that were documented during the hyphema.

Deferiprone is an orally administered iron chelator that has been available since 1999 for the treatment of thalassemia. It has a low molecular weight (139.15 g/mol) and is lipophilic: characteristics ideal for corneal penetration.<sup>5</sup> Apart from a case study showing two incidences of posterior subcapsular deposits associated with systemic deferiprone for thalassemia, there have not been any other ocular complications.<sup>6</sup> This was accepted as a manageable risk compared with penetrating keratoplasty. Furthermore, deferiprone has been used as a substitute in thalassemia patients who have developed desferrioxamine-associated retinal toxicity. In these cases, patients recovered vision from 6/60 to 6/18 following a change in systemic treatment to deferiprone.<sup>7</sup> This suggested that it has a better safety profile than desferrioxamine. The safety data otherwise is sparse in relation to the effect of this drug on the eye.

In the present study, an eye drop of deferiprone was compounded in normal saline to a concentration similar to the mean maximum concentration (C<sub>max</sub> 20 mcg/mL) that would be achieved with standard oral administration (25 mg/kg; 1500 mg) in healthy individuals in a fasting state.<sup>5</sup> It was felt that following topical administration, the ocular penetration of the drug would be lower than 20 mcg/mL, maintaining the drug in the safe range. The half-life of deferiprone is 2 h. An initial 4-week trial of 8 hourly dosage (4 half lives between doses) for 4 weeks did not result in a significant change and therefore a 6 hourly regimen (3 half lives between doses with no overnight dosing) was employed. This resulted in visible changes 2–3 months after introduction of treatment. By 10 months, the cornea had cleared sufficiently to allow optic disc assessment and the vision had improved. At no point during the course of the treatment did the patient experience any side effects. At

final visit, no posterior subcapsular deposits were identified. The endothelial cell density was reduced in the left eye. This could have been due to a combination of the hyphema, high IOP and multiple surgeries. Deferiprone as a cause could not be ruled out. Baseline endothelial cell density measurements could not be performed in the presence of the iron staining.

The rapid rate of clearance of the cornea compared with the previous 12 months where a 'watch and wait' approach was used and the slow rate of clearance following conservative management reported in the literature would suggest that this was a true drug effect (Fig. 1).

To our knowledge, the published literature does not contain any previous cases of this agent being used for corneal blood staining. The optimal strength, dosing and safety profile require a larger series. Topical deferiprone treatment of corneal blood staining if reproduced successfully holds numerous advantages over the other treatment modalities mentioned in the preceding texts. It has the potential of speeding up the process of clearance of the stain from the cornea whilst avoiding further surgical complications.

Thomas Chan MBBS,<sup>1</sup>  
Andrew White PhD FRANZCO,<sup>2</sup>  
Kerrie Meades FRANZCO<sup>1</sup>  
and Chandra Bala PhD FRANZCO<sup>3</sup>

<sup>1</sup>Personaleyes, <sup>2</sup>Westmead Institute, University of Sydney, and <sup>3</sup>Faculty of Medicine and Health Sciences, Macquarie University, Sydney, New South Wales, Australia  
Received 16 November 2016; accepted 16 November 2016.

## REFERENCES

- Messmer EP, Gottsch J, Font RL. Blood staining of the cornea: a histopathologic analysis of 16 cases. *Cornea* 1984; **3**: 205–12.
- Brodrick JD. Corneal blood staining after hyphaema. *Br J Ophthalmol* 1972; **56**: 589–93.
- Fraser C, Liew S, Fitzsimmons R, Arnold J. Spontaneous resolution of corneal blood staining. *Clin Experiment Ophthalmol* 2006; **34**: 279–80.
- Malhotra M, Majumdar DK. Permeation through cornea. *Indian J Exp Biol* 2001; **39**: 11–24.
- Administration FaD. Highlights of prescribing information — ferriprox (deferiprone) tablets, for oral use, 2011. [http://www.accessdata.fda.gov/drugsatfda\\_docs/label/2011/0218251bl.pdf](http://www.accessdata.fda.gov/drugsatfda_docs/label/2011/0218251bl.pdf). Accessed Oct 2015.
- Mehdizadeh M, Nowroozzadeh MH. Posterior subcapsular opacity in two patients with thalassaemia major following deferiprone consumption. *Clin Exp Optom* 2009; **92**: 392–4.
- Wu CH, Yang CP, Lai CC, Wu WC, Chen YH. Deferoxamine retinopathy: spectral domain-optical coherence tomography findings. *BMC Ophthalmol* 2014; **14**: 88.